

A distal coronary artery perforation caused by guidewire

Klavuz tel kaynakli bir distal koroner arter rupturu

Kanber Ocal Karabay^{1*}, Busra Tozlu¹

¹Department of Cardiology, Sancaktepe Sehit Prof.Dr.Ilhan Varank Research and Education Hospital, Istanbul /Turkiye

Abstract

This case report presents a distal coronary artery rupture caused by a guidewire. Although it is generally considered as a benign complication with good prognosis, and less invasive treatment strategies are recommended, the patient required both had to had percutaneous and surgical treatment.

Keywords: coronary angiography, embolization, percutaneous coronary intervention

ÖZ

Bu vaka sunumunda klavuz tele baęlı bir distal koroner arter rüptürü sunulmaktadır. Klavuz tele baęlı koroner rüptürü genelde iyi prognozlu kabul edilse ve tedavi yöntemleri daha çok konservatif olsa da bu vakamızda perkütan ve cerrahi tedavi bir arada gerekmiştir

Anahtar Kelimeler: koroner anjiyografi, embolizasyon, perkütan koroner girişim

Highlights

- Although coronary artery perforations induced by guidewires have been generally considered benign, their treatment can be challenging
- Recommended treatment strategies include reversing anticoagulation with protamine and prolonged balloon inflations
- Various materials including thrombin, collagen, polyvinyl-alcohol, Gelfoam, subcutaneous fat or a part of a balloon can be used for vessel occlusion

Introduction

Coronary artery perforations induced by guidewires have been generally considered benign compared to perforation caused by balloon inflation, stent placement, or the use of debulking devices (1). However, this case report presents a coronary artery distal perforation that required both surgical and percutaneous treatments.

Case Report

A 49-year-old male patient no prior history of coronary artery disease was admitted to the hospital with diagnosis of non-ST elevation myocardial infarction. His psychical examination, transthoracic echocardiography (TTE), ECG, and blood tests were normal except for high troponin level. Coronary angiography revealed totally occluded circumflex artery (CFX) while the other coronary arteries were normal (**Figure 1**).

The patient received ticagrelor 180 mg in addition to aspirin which was given in the emergency room. And the lesion in CFX was successfully treated with a drug-eluting stent (**Figure 2**). However, control injections revealed a distal leakage in CFX (**Figure 2**). Repeated prolonged balloon inflation within the stent was performed, and subsequent contrast injection showed no active leakage. The patient was asymptomatic, and TTE after the procedure showed minimal pericardial effusion. A few hours later, the patient developed mild hypotension (93/60 mmhg) and orthopnea. Repeated TTE showed increased pericardial effusion of less than 2 cm primarily around apex. Clinical signs of tamponade were absent; therefore, percutaneous pericardiocentesis was not performed. However, angiography was performed to rule out any active leakage and it revealed the

*Corresponding author: Kanber Ocal Karabay, Department of Cardiology, Sancaktepe Sehit Prof.Dr.Ilhan Varank Research and Education Hospital, Istanbul /TÜRKIYE. E-mail: ocalkarabay@hotmail.com Received: 24 December 2024 Accepted: 19 January 2025

recurrence of distal coronary leakage. The patient has suffered intermittent complete AV block. The temporary pacemaker was implanted, and a 2.0 x 4 cm Prestige coil was used to occlude distal CFX. Control injections confirmed total occlusion of CFX and no leakage (**Figure 3**). Despite the lack of active coronary leakage and significant pericardial effusion, the patient continued to have mild hypotension and orthopnea. TTE performed the next day revealed a highly echogenic image of the hematoma around the right ventricular free wall, close to apex. Surgical removal of the hematoma resolved the patient's hypotension and orthopnea. The patient was advised to continue aspirin and atorvastatin for life and was discharged in good condition after seven days of hospitalization.

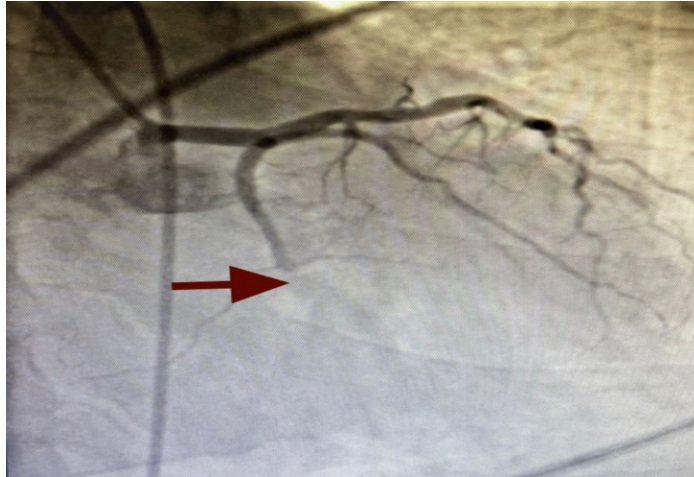

Figure 1. Right anterior oblique caudal view showing total occlusion of the circumflex artery (arrowhead)

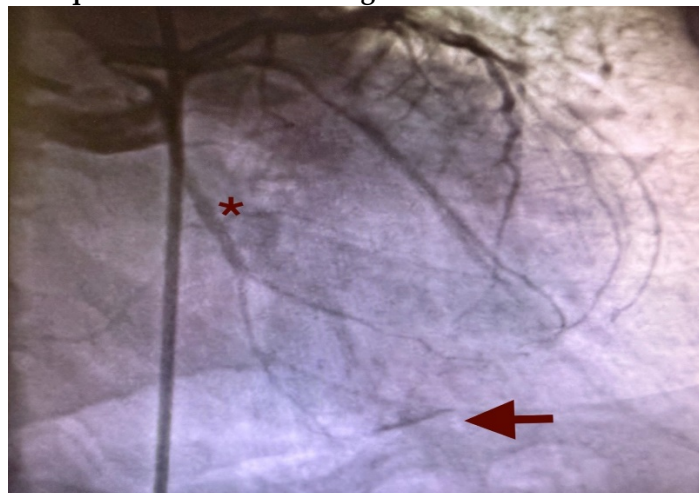


Figure 2. Right anterior oblique caudal view showing distal leakage from the circumflex artery (arrowhead) and stent implanted on mid segment of the circumflex artery (*)

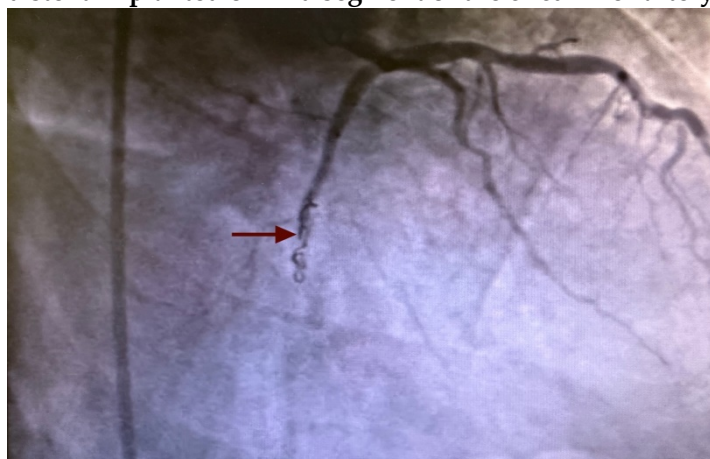


Figure 3. Right anterior oblique caudal view showing occlusion of the circumflex artery with coil (arrowhead)

Discussion

Coronary artery perforation is rare (0.2%-0.6%) but a serious complication of percutaneous coronary intervention (2). Although the guidewire perforations (GWP) are often considered benign, their treatment can be challenging, especially if they are unexpected or poorly managed.

The modified Ellis classification is commonly used to stratify coronary perforations: Type I: extraluminal crater without linear contrast extravasation, suggesting dissection; Type II: myocardial or pericardial blushing; Type III: frank contrast extravasation into the pericardium; and Type IV: perforation with contrast extravasation into the left ventricle, coronary sinus or other vascular areas (3).

Prolonged procedures, stiff or hydrophilic guidewires, and the use of glycoprotein IIb/IIIa platelet inhibitors are common causes of GWP (4). Initially the leakage is often asymptomatic and not associated with significant pericardial effusion on TTE. However, subacute pericardial tamponade may develop (4). In this case, a stiff guidewire was used to cross the total occlusion. TTE after the initial procedure showed no pericardial fluid but significant pericardial effusion noted repeat TTE after few hours.

Although GWPs may initially appear benign on angiography, they frequently evolve into Ellis class III perforations, which are associated with poor prognosis (2). Recommended treatment strategies include reversing anticoagulation with protamine and prolonged balloon inflations (2,3), which have been reported to be successful in >50% of patients (3,5). If leakage persists, distal vessel occlusion is advised (4). Various materials including thrombin, collagen, polyvinyl-alcohol, Gelfoam, subcutaneous fat or a part of a balloon can be used for vessel occlusion (4,6).

In this case, repeated prolonged balloon inflations initially appeared to resolve the leakage. However, distal leakage recurred after a few hours later necessitating coil implantation, which successfully occluded the CFX and distal perforation. Despite this, surgical removal of the pericardial hematoma was required to fully resolve patients' symptoms.

Conclusion

This case highlights the importance of carefully reviewing angiography images in all patients. In the presence of any distal rupture initial echocardiography might appear be normal; therefore, TTE should be performed a few hours later even initial TTE is normal. Persistent distal ruptures despite balloon inflations should be treated aggressively. Additionally, pericardial hematoma should be suspected in patients with pericardial effusion who are experiencing hypotension.

Acknowledgements: None

Ethical Approval: Informed consent for case report was obtained from the patient.

Author Contributions: Concept: KOK, BT. Literature Review: KOK. Design: KOK, BT. Data acquisition: BT. Analysis and interpretation: KOK, BT. Writing manuscript: KOK, BT, Critical revision of manuscript: KOK, BT

Conflict of Interest: The author(s) do not have any potential conflict of interest regarding the research, authorship and/or publication of this article.

Financial Disclosure: This research received no specific grant from any funding agency in the public, commercial, or not-for-profit sectors.

References

1. Stathopoulos I, Panagopoulos G, Kossidas K, et al. Guidewire-induced coronary artery perforation and tamponade during PCI: in-hospital outcomes and impact on long-term survival. *J Invasive Cardiol.* 2014;26(8):371-6.
2. Silva WA, Costa RA, Campostrini T, et al. Incidence, management and prognosis of coronary perforations. *Rev Bras Cardiol Invasiva.* 2012; 20:295-302.
3. Ellis SG, Ajluni S, Arnold AZ, et al. Increased coronary perforation in the new device era. Incidence, classification, management, and outcome. *Circulation.* 1994;90(6):2725-30.
4. Senguttuvan NB, Ramakrishnan S, Gulati GS, et al. How should I treat guidewire-induced distal coronary perforation? *EuroIntervention.* 2012;8(1):155-63.
5. Al-Lamee R, Ielasi A, Latib A, et al. Incidence, predictors, management, immediate and long-term outcomes following grade III coronary perforation. *JACC Cardiovasc Interv.* 2011;4(1):87-95.
6. Sobieszek G, Zięba B. Balloon Fragment Technique Used to Close Distal Coronary Vessel Perforation. *J Invasive Cardiol.* 2020;32(12):370-2.

Cite as: Karabay. KO et al. A distal coronary artery perforation caused by guidewire. *JCMBS* 2025; 5(1):4-6 doi.org/10.5281/zenodo.14656872