

## What do Orthodontists Think About the Diagnosis and Treatment Plan of Patients with Class II Division 1 Skeletal Anomalies? A Preliminary Study

Ortodontistler Sınıf II Bölüm 1 İskelet Anomalisi Olan Hastaların Teşhis ve Tedavi Planı Hakkında Ne Düşünüyor? Bir Ön Çalışması

Ergin Kalkan<sup>1\*</sup>, Yakov Timchuk<sup>1</sup>

<sup>1</sup>Belarussian Medical Academy of Post-Graduate Education (BeLMAPO), Minsk, Belarus

### Abstract

This stud aimed to determine key diagnostic approaches and treatment preferences among orthodontists treating adult patients with Class II Division 1 skeletal anomalies.

**Materials and Methods:** A total of 50 orthodontists participated in this survey-based study.

Ten structured questions were asked regarding diagnostic methods and treatment choices, including bracket systems, torque preferences, imaging techniques, space-creating methods, tooth extraction preferences, malocclusion treatment approaches, and retention strategies. Statistical analyses were performed using chi-square tests for categorical variables, and a p-value < 0.05 was considered statistically significant.

**Results:** Among the participants, 64% preferred traditional braces, while 24% used self-ligating braces. Regarding prescription selection, 56% used McLaughlin, Bennett, Trevisi, 24% Roth, and 20% other systems. Standard torque brackets were preferred by 84% of respondents. For diagnosis, 64% used cephalometric tomography, while 24% relied solely on computed tomography. The most common space-creating approach was distalization (72%), and the most frequently extracted teeth were the upper third molars (52%). The majority (64%) preferred intermaxillary elastics combined with mini-implants for occlusal correction. For retention, 50% used both fixed and removable retainers.

Chi-square analysis (showed) statistically significant associations between years of clinical experience and appliance choice (p < 0.05), as well as between diagnostic modality and preference for surgical versus non-surgical treatment plans (p < 0.05).

**Conclusions:** The study highlights the diversity in orthodontic diagnosis and treatment planning. Most orthodontists favored modern, non-surgical approaches, emphasizing efficiency in treatment duration while balancing aesthetics and functional outcomes.

**Keywords:** Class II Division 1, computed tomography, fixed functional appliances, orthodontic survey, retention

### ÖZ

**Amaç:** Bu çalışma, Sınıf II Bölüm 1 iskeletsel anomalileri olan yetişkin hastaları tedavi eden ortodontistler arasındaki temel tanısal yaklaşımları ve tedavi tercihlerini belirlemeyi amaçlamıştır.

**Gereç ve Yöntem:** Bu ankete dayalı çalışmaya toplam 50 ortodontist katılmıştır. Braket sistemleri, tork tercihleri, görüntüleme teknikleri, yer açma yöntemleri, diş çekimi tercihleri, maloklüzyon tedavi yaklaşımları ve retansiyon stratejileri dahil olmak üzere teşhis yöntemleri ve tedavi tercihleri ile ilgili on yapılandırılmış soru yöneltilmiştir. İstatistiksel analizler kategorik değişkenler için ki-kare testleri kullanılarak yapılmış ve p < 0.05 istatistiksel olarak anlamlı kabul edilmiştir.

**Bulgular:** Katılımcıların %64'ü geleneksel diş tellerini tercih ederken, %24'ü kendinden bağlanan diş tellerini tercih etmiştir. Tedavi sistem seçiminde %56'sı MBT, %24'ü Roth ve %20'si diğer sistemleri seçmiştir. Standart tork braketleri katılımcıların %84'ü tarafından tercih edilmiştir. Teşhis için %64'ü sefalometrik tomografi kullanırken, %24'ü yalnızca bilgisayarlı tomografiye güvenmiştir. En yaygın yer açma yaklaşımı distalizasyondur (%72) ve en sık çekilen dişler üst üçüncü molarlardır (%52). Çoğunluk (%64) oklüzal düzeltme için mini implantlarla birlikte intermaksiller lastikleri tercih etmiştir. Retansiyon için %50'si hem sabit hem de hareketli retainer kullanmıştır.

**Sonuçlar:** Bu çalışma ortodontik tanı ve tedavi planlamasındaki çeşitliliği vurgulamaktadır. Çoğu ortodontist modern, cerrahi olmayan yaklaşımları tercih etmiş, estetik ve fonksiyonel sonuçları dengelerken tedavi süresinde verimliliği vurgulamıştır.

**Anahtar Kelimeler:** Sınıf II Bölüm 1, ortodontik anket, sabit fonksiyonel apareyler, bilgisayarlı tomografi, retansiyon

\*Corresponding author: Ergin Kalkan, Belarussian Medical Academy Of Post-Graduate Education (BeLMAPO), Minsk, Belarus

E-mail: kalkanergin@gmail.com Received: 14 March 2025 Accepted: 21 August 2025

Cite as: Kalkan.E. et al. What do Orthodontists Think About the Diagnosis and Treatment Plan of Patients with Class II Division 1 Skeletal Anomalies? A Preliminary Study. JCMBS 2025; 5(3):0000 doi.org/

### Highlights

- Traditional braces and McLaughlin, Bennett, Trevisi were most preferred.
- Non-extraction approaches with distalization dominated.
- Combined fixed and removable retainers were common.

### Introduction

According to Edward Angle, Class II malocclusion is characterized by the mesiobuccal cusp of the upper first molars being located more mesially than the mesiobuccal fissure of the lower first molars, distocclusion (1,2). Class II malocclusion is one of the most common developmental anomalies, with a prevalence of 15–30% in most populations (2,3), and can lead to serious adverse social, psychological, and aesthetic consequences (4,5). This dentoalveolar anomaly can be divided into two different categories depending on the deficiency of the mandible or the excess development of the maxilla (6,7). This anomaly may present with varying degrees of Class II malocclusion at different ages, which determines the preferred approach in clinical treatment (8).

Class II malocclusion can be divided into two types based on the position of the upper incisors. The most important feature of Class II division 1 malocclusion, which varies between 5-29% in prevalence, is labially inclined upper incisors and increased overjet. This condition may be accompanied by a narrow upper dental arch. Incisor occlusion may vary between deep bite and open bite (8). In Class II Division 2 malocclusion, with a reported prevalence ranging between 1.5% and 11% (5,10–12), the upper incisors are generally retroclination and the mandibular first molars are positioned further back than the upper first molars (13,14). This condition is often accompanied by a deep bite and reduced overjet. Protrusion of the upper incisors or protrusion of the lower incisors due to habits or soft tissues may result in increased overjet regardless of skeletal relationships (9). Individuals with class II division 1 malocclusion often have inadequate lips to perform the task and attempt to compensate through peripheral muscle activity, by rolling the lower lip behind the upper incisors or by moving the tongue forward between the incisors, or through a combination of these elements (9). Thumb sucking or other habits may lead to the development of this malocclusion, often by creating imbalances between the buccinator muscles and tongue force, which narrows the maxillary arch. In addition, these habits often direct the upper incisors forward and the lower incisors backward. Dental characteristics such as tooth size and arch length differences may play a role in the development of class II malocclusion, in which labial movement of the upper incisors may cause increased overjet (9,20). Factors affecting the etiology of malocclusion can be examined in four groups as skeletal, dental, local and soft tissues (3,15-17).

As with other types of malocclusion, class II malocclusion can be diagnosed by clinically accurate assessment of the patient (extraoral and intraoral features), using correct diagnostic tools (anamnesis, photographic analysis, radiographic analysis and plaster analysis) and performing correct functional analysis (postural rest position, maximum intercuspation, temporomandibular joint and orofacial dysfunction examination) (18, 19). Class II malocclusion is defined when the mesiobuccal cusp of the upper permanent first molar is positioned mesially from the mesial fissure of the lower permanent first molar by more than half of its width (12). Patients with class II division 1 malocclusion usually have a convex profile, dolichocephalic head shape, deepened mentolabial sulcus, and mental muscle activity (11, 18). Morphologically different structures or teeth that are inclined mesially/distally may lead to misinterpretation of class II malocclusion (10). The components of skeletal class II malocclusion can be classified according to the maxillo-mandibular jaw relationship, skull base size, vertical dimension discrepancy and occlusion plane status (10).

Skeletal Class II anomalies are characterized by mandibular deficiency of 80%, maxillary excess of 20% or posterior positioning of the condyle within the glenoid fossa (19). In patients with growth potential, mandibular deficiency can be treated with fixed or removable functional appliances that change the anteroposterior and vertical positions of the mandible, reshape the condyle and stimulate mandibular growth. In addition, headgears are used to restrict or redirect growth in the maxilla in Class II patients with maxillary excess and growth potential (19). In individuals with completed craniofacial growth, treatment options include intraoral or extraoral distalization appliances, tooth extractions, and orthognathic surgery to skeletal Class II anomalies. Factors such as the origin of the anomaly maxillary or mandibular factors such as the severity of the discrepancy, the patient's growth stage, growth potential, and soft tissue profile are also considered in treatment planning (20).

Consequently, treatment strategies are tailored to these individual factors. Surveys are structured instruments used to collect information on individuals' attitudes, perceptions, experiences, and preferences (20). Considering the difficulties encountered during the COVID-19 pandemic and quarantine period while collecting data, survey studies have gained importance.

This study aimed to evaluate the diagnostic methods and treatment preferences of orthodontists managing adult patients with Class II Division 1 skeletal malocclusions, focusing on bracket systems, torque selection, imaging techniques, space creation, extraction patterns, correction strategies, and retention protocols. Additionally, it assessed associations between clinical experience, diagnostic choices, and treatment decisions.

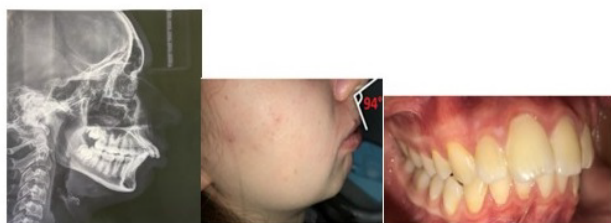
## Material and Methods

### Study design and data collection

This was a preliminary cross-sectional survey study. While preparing the questions, the most frequently used and up-to-date techniques in the diagnosis and treatment of (Class II Division 1 skeletal anomalies) in the literature were taken into consideration. The survey included questions on years of clinical experience, workplace type (public or private), bracket system preference, prescription type selection, torque selection for maxillary incisors, preferred imaging method, space-creating technique, tooth extraction choices (if applicable), malocclusion treatment methods, and retention strategies.

A printed survey consisting of 10 questions was randomly distributed to 64 certified orthodontists who received training in the Republic of Belarus, and 50 of them completed the survey. Participants were randomly selected regardless of gender or professional experience. Informed consent was obtained from the participants. The data collection period was set at 3 months. (Figure 1)

We kindly ask you to participate in the survey conducted by the Department of Prosthetics, Pediatric Dentistry and Orthodontics. The aim of this study is to determine the main aspects of diagnostic and treatment options for adult patients with skeletal class II division 1 anomalies. For this, please answer the questions in the survey. To complete the survey, please mark the appropriate answer from the diagnostic and treatment options in the patient sample with the necessary information in the suggested list or enter the necessary information in the blank lines. Thank you for your participation.



**Figure 1.** Cephalometric X-ray, intraoral and extraoral photographs of the patient

Cephalometric analysis result:  $SNA=85^{\circ}\uparrow$ ,  $SNB=79^{\circ}\downarrow$ ,  $ANB=6^{\circ}\uparrow$ ,  $SN-NL=7^{\circ}\leftrightarrow$ ,  $SN=ML-30^{\circ}\downarrow$ ,  $NL-ML=25^{\circ}\uparrow$ ,  $I-SN=119^{\circ}\uparrow$ ,  $I-NL=117^{\circ}\uparrow$ ,  $I-MP=114^{\circ}\uparrow$

1- How many years of professional experience do you have?

- a) 1-5                      b) 5-10                      c) 10-15

2- Which organization do you work in?

- a) In a government institution                      b) In a private institution

3- Which type of brackets do you prefer?

- a) Self ligating system                      b) Ligating system

4- Which prescription do you prefer?

- a) Roth                      b) MBT                      c) Edge wise                      d) Others

5- What type of torque bracket system do you prefer for the upper anterior incisors?

- a) Bracket system with high torque  
b) Bracket system with low torque  
c) Bracket system with standard torque

6- What type of imaging do you prefer for diagnosis?

- a) Cephalometric X-ray  
b) Panoramic X-ray  
c) Computerized tomography  
d) Magnetic resonance imaging

7- Which method would you choose to create space in the dental arch?

- a) Tooth extraction                      b) Molar distalization                      c) Inter proximal reduction

8- Which tooth or teeth do you prefer to extract in treatment with extraction?

- a) Upper first premolars                      b) Upper second premolars                      c) Upper third molars

9- Which method do you prefer for the treatment of malocclusion?

- a) Intermaxillary elastics                      b) Orthodontic screw                      c) Fixed functional class II mechanics

10- Which method do you prefer for retention treatment after orthodontic treatment?

- a) Removable retainer                      b) fixed retainer                      c) Both fixed and removable retainers

**Figure 1: Survey sample**

### Sample size determination and statistical analysis

The study determined the necessary sample size using a priori power analysis by G\*Power software (ver. 3.1.9.4; Heinrich-Heine-Universität Düsseldorf, Düsseldorf, Germany) (21). To determine the required sample size and ensure the study's statistical power, a power analysis was conducted with the following parameters: Incidence in the general population: 78%, Incidence in the study group: 64%, Alpha (Type I error probability): 0.05, Beta (Type II error probability): 0.2, Statistical power: 0.8, Required sample size (N): 75.

While the sample size of 50 orthodontists was slightly below the ideal 75, the statistical power of 0.8 was considered sufficient for detecting true differences in treatment preferences. Future studies with a larger sample size would enhance the reliability and generalizability of the findings. Statistical analyses were performed using the chi-square test for categorical data, and  $p < 0.05$  were considered statistically significant.

### Ethical Approval

The study protocol was approved by the Institutional Ethics Committee of the Belarusian Medical Academy of Post-Graduate Education (Approval number: 109, dated 19.07.2021). The study was conducted in accordance with the Declaration of Helsinki. Informed consent was obtained from all participants

### Results

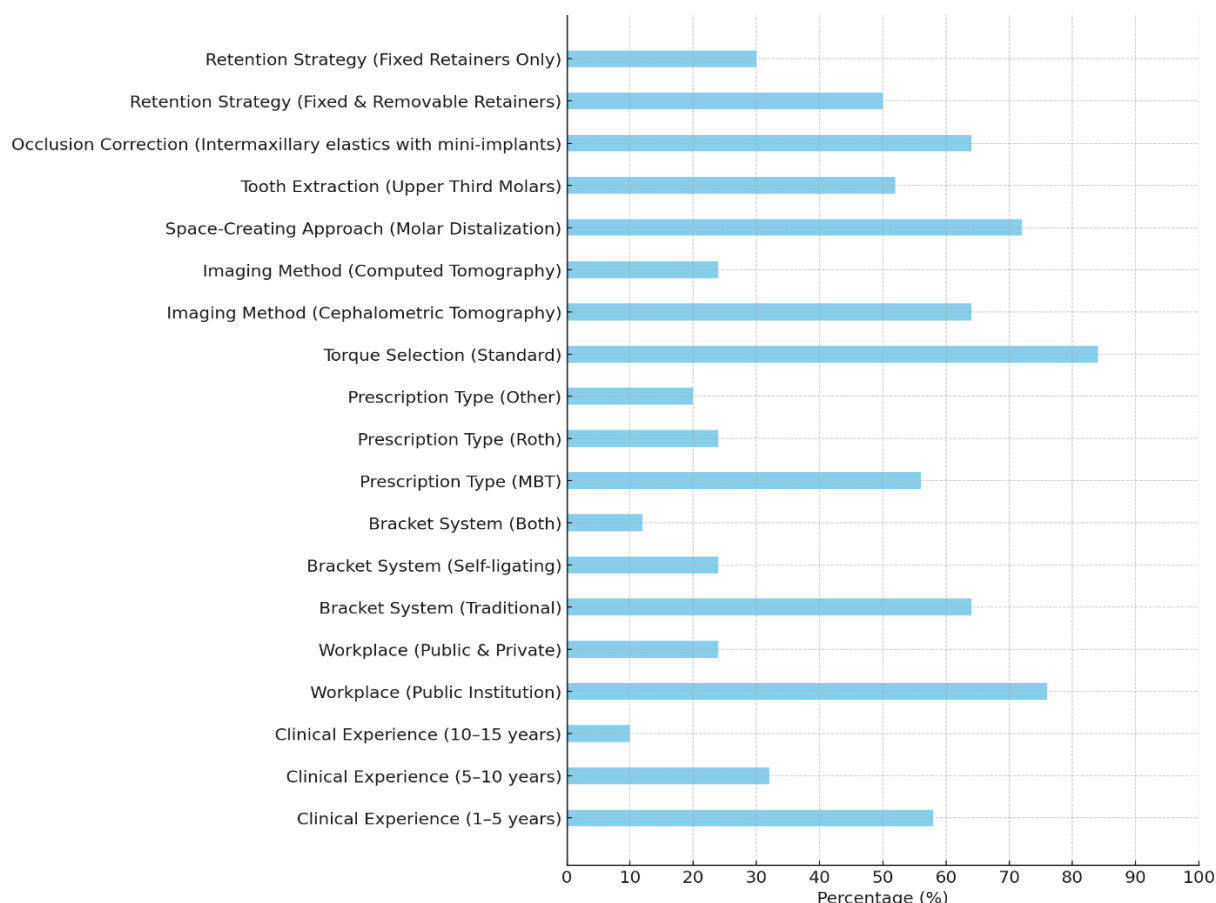
A summary of orthodontists' preferences in diagnosing and treating Class II Division 1 malocclusion is presented in **Table 1**. Most respondents were early-career professionals working in public institutions and favored traditional braces and the MBT prescription system. Standard torque brackets and cephalometric tomography were commonly used for diagnosis. Molar distalization was the preferred method for space creation, while upper third molars were the most frequently extracted teeth. For retention, a combination of fixed and removable retainers was the most commonly used approach, emphasizing individualized post-treatment care.

A Figure visualizing orthodontists' preferences in diagnosing and treating Class II Division 1 malocclusion based on the survey data is presented in **Figure 2**. It highlights various factors such as clinical experience, workplace setting, treatment choices, and retention strategies.

**Table 1. Summary of orthodontists' preferences in the diagnosis and treatment of Class II Division 1 malocclusion, including clinical experience, treatment modalities, and retention strategies.**

Category	Preference / Outcome	Percentage (%)
Clinical Experience	1–5 years	58
	5–10 years	32
	10–15 years	10
Workplace	Public institution	76
	Public & private sector	24
Bracket System	Traditional braces	64
	Self-ligating braces	24
	Both	12
Prescription Type	MBT	56
	Roth	24
	Other	20
Torque Selection	Standard torque brackets	84
Imaging Method	Cephalometric tomography	64
	Computed tomography	24
Space-Creation Approach	Molar distalization	72
Tooth Extraction	Upper third molars	52
Occlusion Correction	Intermaxillary elastics with mini-implants	64
Retention Strategy	Fixed & removable retainers	50
	Fixed retainers only	30





**Figure 2. Orthodontists' Preferences in the Diagnosis and Treatment of Class II Division 1 Malocclusion (Chi-square Analysis)**

### Discussion

The findings indicate a preference for modern, non-surgical approaches in the treatment of Class II Division 1 malocclusion. Traditional bracket systems, MBT prescriptions, and standard torque brackets remained dominant choices. Imaging modalities, particularly cephalometric tomography, played a critical role in diagnosis. For space creation and occlusal correction, molar distalization and mini-implants were frequently preferred. Retention strategies varied, with an equal distribution between fixed and removable retainers.

More conservative and patient-friendly treatment modalities, minimizing invasive procedures while maintaining efficiency and aesthetic outcomes. The statistical significance of these findings ( $p < 0.05$ ) reinforces the reliability of the observed trends.

Recent research has emphasized the role of skeletal anchorage systems in optimizing outcomes for Class II Division 1 patients. Temporary anchorage devices (TADs) have been shown to improve distalization efficiency, reduce the need for premolar extractions, and provide more stable long-term occlusal results (2). This aligns with our findings, where mini-implants were commonly employed for occlusion correction.

Similarly, advances in three-dimensional imaging have improved diagnostic precision. Cone-beam computed tomography (CBCT) enables more accurate assessment of skeletal discrepancies and airway dimensions, thereby facilitating personalized treatment planning (22). Although cephalometric tomography was predominantly used among our respondents, wider integration of CBCT could further refine clinical decision-making.

Long-term stability remains a major concern in Class II Division 1 management. Meta-analyses suggest that functional appliance therapy combined with fixed orthodontics produces more stable results than fixed appliances alone (23). This highlights the importance of incorporating functional orthopedic interventions during early treatment to optimize stability and reduce relapse risks. Nonetheless, studies have found no significant differences between early (two-stage) and late treatment outcomes (24). Regarding extraction therapy, Booij et al. (25) demonstrated stable results with first permanent molar extraction, while most participants in our study preferred first premolar extraction. Although self-ligating systems were chosen by many participants, Maizeray et al. (26) reported no significant clinical differences between self-ligating and conventional brackets.

Future research should emphasize the integration of digital workflows and artificial intelligence-driven diagnostic tools to improve efficiency and predictability. Expanding studies to include larger, multinational cohorts would also help diversify perspectives and enhance generalizability. Longitudinal designs are necessary to assess relapse rates and long-term stability.

In conclusion, this study highlights the ongoing evolution of diagnostic and therapeutic strategies for Class II Division 1 malocclusion. The preference for modern, minimally invasive approaches reflects a growing emphasis on patient comfort, aesthetics, and treatment efficiency. The paradigm shifts toward molar distalization supported by skeletal anchorage systems underscores the move away from extractions. Importantly, individualized treatment planning—considering patient age, growth potential, and soft tissue characteristics—remains central to successful outcomes. Although the limited sample size and geographic scope warrant caution in interpretation, these findings provide valuable insight into current trends. Moreover, the integration of artificial intelligence and digital workflow technologies could further enhance diagnostic accuracy, improve treatment efficiency, and standardize care.

### Study limitations

This preliminary study has certain limitations. The relatively small sample size (n=50) reduces statistical power and limits the generalizability of the findings. Furthermore, all participants were orthodontists trained in a single country, which may not capture global variations in diagnostic and treatment approaches. The reliance on self-reported survey data may also introduce recall bias and subjective interpretation. Finally, as this study provides only a cross-sectional snapshot, future multi-center and longitudinal studies with larger cohorts are required to validate these findings and assess long-term treatment stability.

### Conclusion

In conclusion, this study highlights evolving trends in the management of Class II Division 1 malocclusion, emphasizing modern, patient-centered, and minimally invasive approaches. The findings suggest that integrating advanced imaging, skeletal anchorage systems, and digital technologies can enhance diagnostic precision and treatment efficiency while reducing reliance on extractions and surgical procedures. Future studies should validate these results through larger, multi-center, and longitudinal studies to assess long-term stability. Moreover, the incorporation of artificial intelligence in treatment planning holds promise for more accurate and predictive outcomes. Ongoing refinement of diagnostic and therapeutic strategies will be essential to optimize results and maintain a strong focus on patient-centered care.

---

**Acknowledgements:** None.

**Ethical Approval:** This Study approval was obtained from the Institutional Ethics Committee of the Belarussian Medical Academy of Post-Graduate Education institution (number: 109 date :19.07. 2021). Informed consent was obtained from all participants.

**Author Contributions:** Concept: K.E, T.Y. Literature Review: K.E, T.Y. Design: K.E, T.Y. Data acquisition: K.E, T.Y. Analysis and interpretation: K.E, T.Y. Writing manuscript: K.E, T.Y. Critical revision of manuscript: K.E, T.Y.

**Conflict of Interest:** The author(s) do not have any potential conflict of interest regarding the research. authorship and/or publication of this article.

**Data Availability:** The data used to support the findings of this study are available from the corresponding author upon request.

**Financial Disclosure:** none

---

### References

1. Flis PS. Orthodontics. Medicine Publisher; 2008. p. 27–29.
2. Elkordy SA, Aboelnaga AA, Fayed MS, et al. Can the use of skeletal anchors in conjunction with fixed functional appliances promote skeletal changes? A systematic review and meta-analysis. *Eur J Orthod.* 2016;38(5):532–45.
3. Vasquez MJ, Baccetti T, Franchi L, et al. Dentofacial features of Class II malocclusion associated with maxillary skeletal protrusion: a longitudinal study at the circumpubertal growth period. *Am J Orthod Dentofacial Orthop.* 2009;135(5):568.e1–7; discussion 568–9.
4. Kiekens RM, Maltha JC, Hof MA, et al. Objective measures as indicators for facial esthetics in white adolescents. *Angle Orthod.* 2006;76(4):551–7.
5. Tehrani A, Behnia H, Younessian F. Bipolar disorder: review of orthodontic and orthognathic surgical considerations. *J Craniofac Surg.* 2015;26(4):1321–5.
6. Bishara SE. Class II malocclusions: diagnostic and clinical considerations with and without treatment. *Semin Orthod.* 2006;12(1):11–24.
7. Woodside DG. The present role of the general practitioner in orthodontics. *Dent Clin North Am.* 1968;12(2):83–5.

8. Tehranchi A, Behnia H, Younessian FA. Advances in management of Class II malocclusions. In: Textbook of Advanced Oral and Maxillofacial Surgery. 7th ed. IntechOpen; 2016. p. 1–2.
9. Coskuner HG, Ciger S. Three-dimensional assessment of the temporomandibular joint and mandibular dimensions after early correction of the maxillary arch form in patients with Class II Division 1 or Division 2 malocclusion. *Korean J Orthod.* 2015;45(3):121–9.
10. Shaughnessy T, Shire L. Etiology of Class II malocclusions. *Pediatr Dent.* 1988;10(4):336–8.
11. Baccetti T, Franchi L, McNamara JA, et al. Early dentofacial features of Class II malocclusion: a longitudinal study from the deciduous through the mixed dentition. *Am J Orthod Dentofacial Orthop.* 1997;111(5):502–9.
12. Craig CE. The skeletal patterns characteristic of Class I and Class II, Division I malocclusions in norma lateralis. *Angle Orthod.* 1951;21(1):44–56.
13. Yousefian J, Trimble D, Folkman G. A new look at the treatment of Class II Division 2 malocclusions. *Am J Orthod Dentofacial Orthop.* 2006;130(6):771–8.
14. Sassouni V. A classification of skeletal facial types. *Am J Orthod.* 1969;55(2):109–23.
15. Mohammed A. Aetiology of malocclusion: definition Malocclusion lecture notes. University of Glasgow; 2013. p. 4.
16. Özel N, Aksoy A. Functional orthopedic appliances used in the treatment of Class II malocclusion. *Smyrna Med J.* 2011; 1:48–51.
17. Slideplayer.com. The etiology of Class II malocclusion [Internet]. 2015 [cited 2025 Apr 8]. Available from: <https://slideplayer.com/slide/1702453/>
18. Moyers RE, Riolo ML, Guire KE, et al. Differential diagnosis of Class II malocclusions: Part 1. Facial types associated with Class II malocclusions. *Am J Orthod.* 1980;78(5):477–94.
19. Pfeiffer J, Grobety D. The Class II malocclusion: differential diagnosis and clinical application of activators, extraoral traction, and fixed appliances. *Am J Orthod.* 1975;68(5):499–544.
20. Flis PS, Kasianenko DM. Necessity of elimination of etiologic factors by means of cooperation with different specialization doctors in the treatment of distal occlusion. *Ukr Dent J.* 2022;(4):51–4.
21. Isik M, Altuntas M, Atayoglu AT. Evaluation of knowledge and attitudes of family medicine residents on traditional and complementary medicine: a descriptive comparative study. *JCMBS.* 2023;3(1):51–8.
22. Al-Mozany SA, Dalci O, Almuzian M, et al. A novel method for treatment of Class III malocclusion in growing patients. *Prog Orthod.* 2017;18(1):40.
23. Perinetti G, Primožič J, Franchi L, et al. Treatment effects of removable functional appliances in pre-pubertal and pubertal Class II patients: a systematic review and meta-analysis of controlled studies. *PLoS One.* 2015;10(10):e0141198.
24. Veitz-Keenan A, Liu N. One phase or two phase orthodontic treatment for Class II Division 1 malocclusion? *Evid Based Dent.* 2019;20(3):72–3.
25. Booij WJ, Kuijpers AM, Bronkhorst EM, et al. Class II Division 1 malocclusion treatment with extraction of maxillary first molars: evaluation of treatment and post-treatment changes by the PAR index. *Orthod Craniofac Res.* 2021;24(1):102–10.
26. Maizeray R, Wagner D, Lefebvre F, et al. Is there any difference between conventional, passive and active self-ligating brackets? A systematic review and network meta-analysis. *Int Orthod.* 2021;19(4):532–8.